


CASE REPORT**Gastroenterology**

A case of Burkitt Lymphoma discovered by digital rectal exam

Colin Winke¹ | Brandon Moore¹ | Jacob Gelman¹ | Stephan Paul² |
Audra Rouster¹ | Amy Guido¹ 

¹Department of Pediatrics, Division of Pediatric Gastroenterology and Hepatology, West Virginia University School of Medicine, Morgantown, West Virginia, USA

²Department of Pediatrics, Section of Hematology/Oncology, West Virginia University School of Medicine, Morgantown, West Virginia, USA

Correspondence

Amy J. Guido, MD, MS, Department of Pediatrics, Division of Pediatric Gastroenterology, Hepatology, and Nutrition, West Virginia University, 64 Medical Center Dr, PO Box 9214, Morgantown, WV 26506, USA.

Email: amy.guido@hsc.wvu.edu

Funding information

None

Abstract

Burkitt Lymphoma (BL) is an aggressive B-cell lymphoma predominantly encountered in pediatrics. Sporadic type typically involves the abdomen and/or pelvis. We present an 8-year-old Caucasian male with vomiting, weight loss, fatigue, and abdominal pain. An abdominal X-ray was unremarkable without any acute findings. Pediatric gastroenterology was consulted and recommended esophagogastroduodenoscopy and colonoscopy. A digital rectal exam (DRE) was performed, and a firm lesion was palpated. The colonoscopy was normal. Subsequent magnetic resonance imaging and computed tomography scans revealed a lesion in the left lower quadrant with mass-like processes involving the porta hepatis and encasing the left distal ureter. Tissue biopsy confirmed BL. The patient completed chemotherapy and achieved remission. This case highlights DRE as a basic physical exam skill in the evaluation of patients with nonspecific gastrointestinal symptoms.

KEYWORDS

colonoscopy, gastroenterology, physical examination, vomiting, weight loss

1 | INTRODUCTION

Originally described in 1958, Burkitt Lymphoma (BL) is the most common non-Hodgkin lymphoma (NHL) and third most common lymphoid malignancy in children less than 15 years of age. BL accounts for 40% of all childhood NHL and can be divided into the three distinct categories—sporadic, endemic, and immunodeficiency-related.^{1–3} Sporadic BL tends to be most common in non-Hispanic white males aged 3–5 years.³

Of all cases of BL, 60–80% present within the abdomen.³ As such, BL can present with nonspecific gastrointestinal (GI) symptoms including abdominal pain, nausea, vomiting, and GI bleeding.⁴ BL is the fastest growing human tumor with a doubling time between 24 and 48 h, and as such, 70% of newly diagnosed patients present with advanced stage disease.^{5,6} BL can have a silent presentation, which can delay diagnosis.⁷ We present a case where

diagnosis was complicated by vague symptoms but suspected after digital rectal exam (DRE).

2 | CASE REPORT

A fully vaccinated 8-year-old male presented to the emergency department (ED) with nausea, vomiting, and diarrhea for 1 week after returning from vacation in Texas. Nonbloody and nonbilious vomiting occurred every few hours leading up to presentation in the ED. Diarrhea was watery and without blood. He had poor oral intake and diffuse crampy abdominal pain. He denied fever, night sweats, rash, shortness of breath, upper respiratory symptoms, or decreased urine output. The remainder of his history was unremarkable.

In the ED, he was hypertensive (120/80 mmHg) but his vital signs were otherwise stable. He was described as ill-appearing and listless. Physical exam revealed

This is an open access article under the terms of the [Creative Commons Attribution-NonCommercial-NoDerivs](https://creativecommons.org/licenses/by-nc-nd/4.0/) License, which permits use and distribution in any medium, provided the original work is properly cited, the use is non-commercial and no modifications or adaptations are made.

© 2024 The Authors. *JPGN Reports* published by Wiley Periodicals LLC on behalf of The European Society for Pediatric Gastroenterology, Hepatology, and Nutrition and the North American Society for Pediatric Gastroenterology, Hepatology, and Nutrition.

moist mucous membranes, hypoactive bowel sounds, and a soft, tender abdomen in the bilateral upper quadrants and suprapubic region. Ondansetron did not improve his nausea. The patient had one episode of coffee-ground emesis while in the ED and failed an oral hydration challenge.

A complete blood count (CBC) was remarkable for a platelet count of 426,000 per μL and a white blood cell count (WBC) of 12,700 per μL . WBC differential was unremarkable (absolute neutrophil count 9190 per μL). A comprehensive metabolic panel (CMP) was largely unremarkable except for a mild anion gap of 16 mmol/L. C-reactive protein (CRP) was 24 $\mu\text{g}/\text{mL}$, and erythrocyte sedimentation rate (ESR) was 33 mm/hour. A streptococcus pyogenes polymerase chain reaction (PCR) was negative. Urinalysis was positive for ketones. Lipase was unremarkable. A KUB showed no evidence of obstruction or perforation. The patient was admitted for observation and further evaluation of hematemesis.

The patient was diagnosed with infectious gastroenteritis with suspected Mallory-Weiss tear related to recurrent emesis. The patient's nausea gradually resolved on ranitidine and ondansetron. He was able to tolerate a full meal by hospital day two with no further hematemesis, so he was discharged.

One month later, the patient returned to the ED for intermittent episodes of nausea and vomiting, fatigue, anorexia, diffuse abdominal pain, and weight loss. On initial exam, the patient was ill-appearing, tachycardic (127 bpm), and hypertensive (122/80 mmHg) to greater than the 95th percentile for his age and height. Growth chart demonstrated a 7 lb weight loss over 1 month. Physical exam revealed a soft but diffusely tender abdomen with no rebound tenderness or guarding.

A KUB showed a nonobstructive bowel gas pattern. A CBC, CMP, and lipase were similar to prior studies. Thyroid stimulating hormone was normal. CRP and ESR remained elevated at 68 mg/L and 40 mm/h, respectively. He again failed oral hydration challenges and was admitted. Pediatric gastroenterology was consulted and recommended esophagogastroduodenoscopy (EGD) and colonoscopy.

EGD identified distal esophagitis and gastritis. Before the colonoscopy, a DRE under sedation was performed by the endoscopist. A hard lesion was palpated along the anterior wall of the rectum. The colonoscopy was unremarkable, and a retroflexed view in the rectum found no visible abnormalities (Figure 1).

Due to an abnormal DRE, a pelvic magnetic resonance imaging was recommended and revealed generalized ascites and a partially visualized rounded soft tissue mass in the anterior left lower quadrant of the abdomen. The mass extended into the anatomic pelvis abutting the posterior bladder. Narrowing of the rectosigmoid colon was appreciated secondary to the soft tissue mass (Figure 2). A follow up abdominal

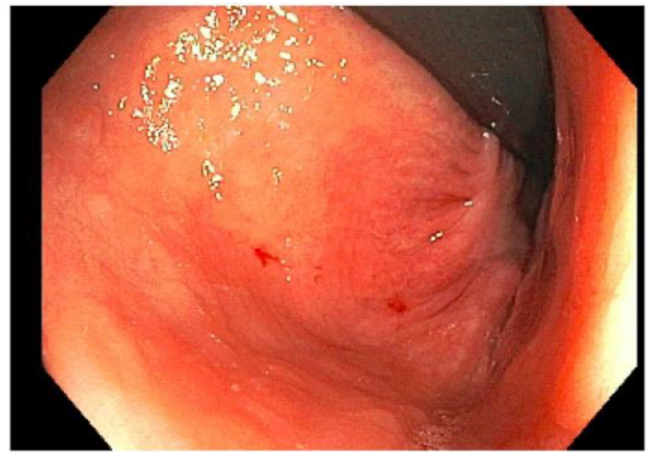


FIGURE 1 A retroflexed view of the rectum during colonoscopy which shows normal tissue and no evidence of mass.

and pelvic computed tomography showed a diffuse infiltrative heterogeneous mass-like process throughout the mesentery and porta hepatis with associated ascites and peritoneal thickening (Figure 3). The distal left ureter was encased by the infiltrative process causing proximal left sided grade two hydronephrosis.

Pediatric nephrology, hematology, urology, and surgery were consulted. A lactate dehydrogenase was obtained and noted to be elevated at 483 U/L, but there was no evidence of tumor lysis syndrome. Pediatric surgery performed an exploratory laparotomy. Ascites fluid analysis and tissue biopsies were remarkable for High Grade B-Cell Lymphoma/BL. Fluorescent in-situ hybridization analysis revealed the characteristic translocation of BL, $t(8; 14)$. Evaluation for Epstein Bar Virus via Epstein Bar encoding region analysis was negative. The patient went on to receive chemotherapy. He is now 4 years post-treatment and remains in remission.

3 | DISCUSSION

Diagnosis of BL in this patient was complicated by vague initial symptoms. Persistence of symptoms and weight loss between admissions necessitated further investigation. Even then, an infectious process versus inflammatory bowel disease were still favored on differential diagnosis considering elevated CRP and ESR.

The DRE performed under anesthesia before colonoscopy was critical in making the diagnosis. Visual inspection of the GI tract and biopsies obtained were unremarkable. If the mass was not palpated by DRE, abdominal imaging may not have been pursued as quickly, and the diagnosis may have been further delayed.

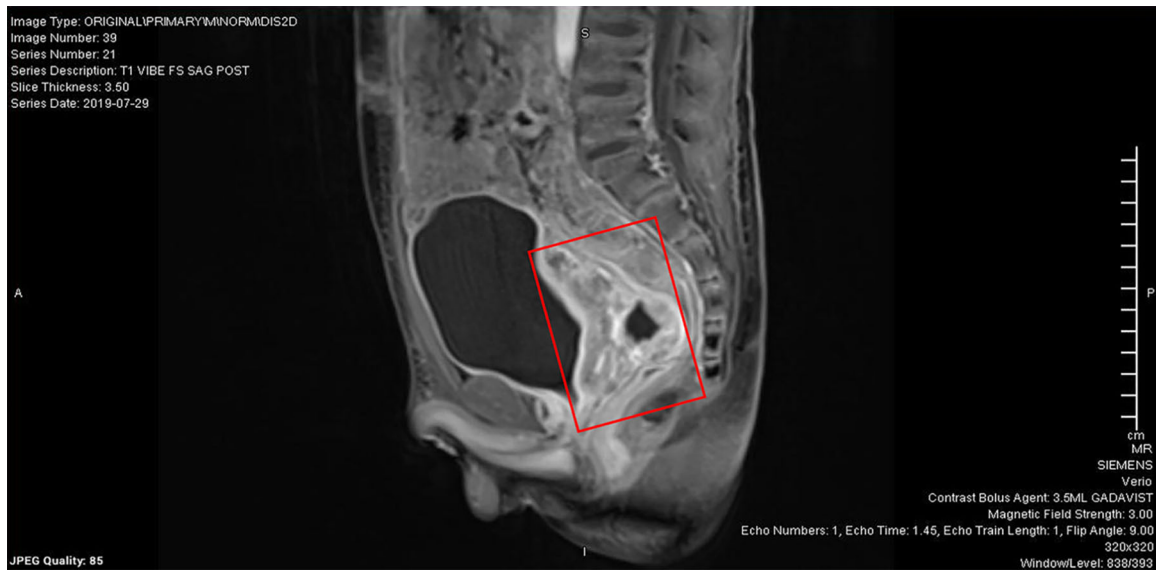


FIGURE 2 A sagittal view of the mass on pelvic MRI with contrast revealing compression of the rectosigmoid colon. MRI, magnetic resonance imaging.

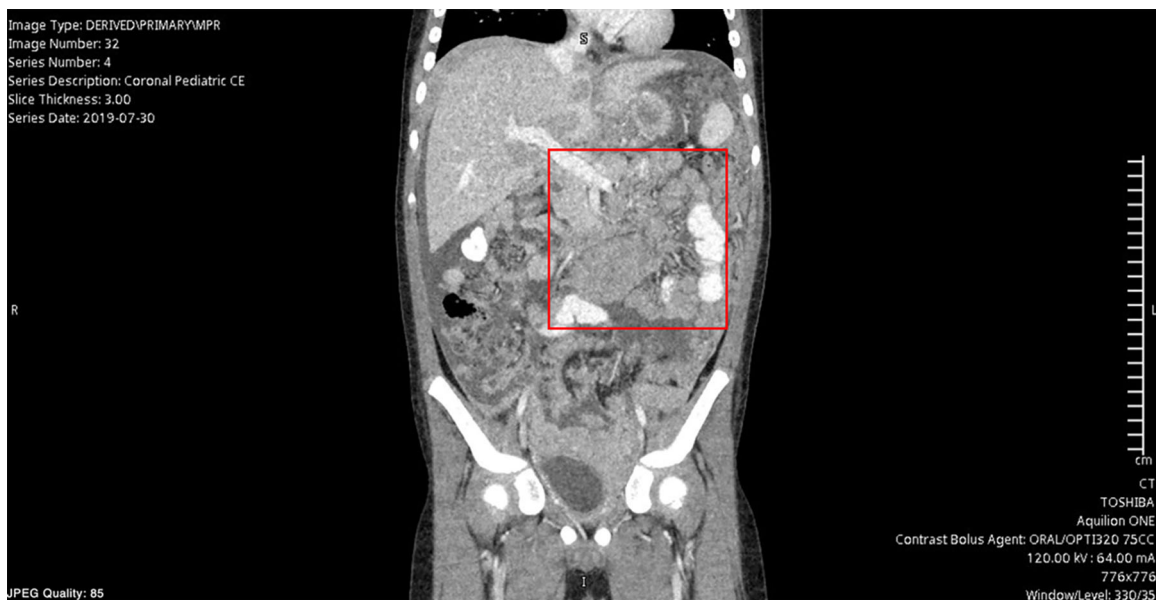

FIGURE 3 A coronal view on abdominal CT of the mass-like process involving the mesentery and porta hepatis. CT, computed tomography.

A DRE can provide valuable insight in formulating a differential diagnosis. It is indicated in cases of GI bleeding, abdominal pain, constipation, fecal incontinence, diarrhea, anemia, urinary symptoms, and more. However, it is an exam frequently deferred by providers. One study which reviewed the cases of 1140 children presenting to an ED for abdominal pain found that less than 5% of patients had a DRE.⁸ DREs are often deferred for a multitude of reasons including lack of training, discomfort, embarrassment, and anticipated refusal.⁹ In addition, large professional bodies such as the North American Society for

Pediatric Gastroenterology Hepatology and Nutrition (NASPGHAN), do not recommend a DRE for evaluation of GI complaints such as functional constipation.¹⁰

Whether the DRE is not being performed for the myriad of reasons above or other reasons not discussed here, the significance of this physical exam skill cannot be understated. The inability of the healthcare provider to confidently and correctly perform a DRE when necessary can have striking impacts on patient outcomes and the quality of care provided. Furthermore, as demonstrated in this case, endoscopic findings may not adequately assist in the

diagnosis of occult pathologies if performed independently from a DRE.

BL is an aggressive B-cell lymphoma that commonly involves the abdomen and most commonly presents in the pediatric-aged population. Expedient diagnosis and treatment are critical to improved prognosis due to its rapid progression. This case is an excellent example of how careful attention to physical exam can direct one's differential diagnosis, lead to a more rapid diagnosis, and positively impact patient outcomes.

CONFLICT OF INTEREST STATEMENT

The authors declare no conflict of interest.

ETHICS STATEMENT

Informed consent from the patient's parents was obtained for publication of the case details.

ORCID

Amy Guido  <http://orcid.org/0000-0003-2368-0419>

REFERENCES

- Burkitt D. A sarcoma involving the jaws in African children. *Br J Surg*. 1958;46:218-223.
- Bishop PC, Rao VK, Wilson WH. Burkitt's lymphoma: molecular pathogenesis and treatment. *Cancer Invest*. 2000;18:574-583.
- Mbulaiteye SM, Biggar RJ, Bhatia K, Linet MS, Devesa SS. Sporadic childhood Burkitt lymphoma incidence in the United States during 1992-2005. *Pediatr Blood Cancer*. 2009;53:366-370.
- Blum KA, Lozanski G, Byrd JC. Adult Burkitt leukemia and lymphoma. *Blood*. 2004;104(10):3009-3020. doi:10.1182/blood-2004-02-0405
- Jaffe ES. The 2008 WHO classification of lymphomas: implications for clinical practice and translational research. *Hematology*. 2009;2009:523-531.
- Casulo C, Friedberg JW. Burkitt lymphoma- a rare but challenging lymphoma. *Best Pract Res Clin Haematol*. 2018;31:279-284.
- Miron I, Miron L, Lupu VV, Ignat A. Silent presentation of multiple metastasis Burkitt lymphoma in a child: a case report and review of the literature. *Medicine*. 2017;96(28):e7518. doi:10.1097/MD.00000000000007518
- Scholer SJ, Pituch K, Orr DP, Dittus RS. Use of the rectal examination on children with acute abdominal pain. *Clin Pediatr*. 1998;37(5):311-316.
- Orenstein SR, Wald A. Pediatric rectal exam: why, when, and how. *Curr Gastroenterol Rep*. 2016;18(1):4. doi:10.1007/s11894-015-0478-5
- Tabbers MM, DiLorenzo C, Berger MY, et al. Evaluation and treatment of functional constipation in infants and children: evidence-Based recommendations from ESPGHAN and NASP-GHAN. *J Pediatr Gastroenterol Nutr*. 2014;58(2):258-274. doi:10.1097/MPG.0000000000000266

How to cite this article: Winke C, Moore B, Gelman J, Paul S, Rouster A, Guido A. A case of Burkitt Lymphoma discovered by digital rectal exam. *JPGN Rep*. 2024;1-4. doi:10.1002/jpr3.12077