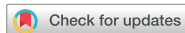

Original Article



Therapeutic Effect of Table Salt on Gastrostomy Granulomas in Pediatric Patients: A Prospective Study

Jack J. Hachem ,^{1,2} Thu Pham ,^{1,2} Ankona Banerjee ,² and James Noel ^{1,2}

¹Department of Pediatric Gastroenterology, Children's Hospital of San Antonio, San Antonio, TX, USA

²Department of Pediatric Gastroenterology, Baylor College of Medicine, Houston, TX, USA



Received: Jun 20, 2024

Revised: Aug 21, 2024

Accepted: Dec 1, 2024

Published online: Mar 5, 2025

Correspondence to

Jack J. Hachem

Department of Pediatric Gastroenterology,
Children's Hospital of San Antonio, 333 N Santa
Rosa, San Antonio, TX 78207, USA.
Email: Hachem@bcm.edu

Copyright © 2025 by The Korean Society of
Pediatric Gastroenterology, Hepatology and
Nutrition

This is an open-access article distributed
under the terms of the Creative Commons
Attribution Non-Commercial License ([https://
creativecommons.org/licenses/by-nc/4.0/](https://creativecommons.org/licenses/by-nc/4.0/))
which permits unrestricted non-commercial
use, distribution, and reproduction in any
medium, provided the original work is properly
cited.

ORCID iDs

Jack J. Hachem
<https://orcid.org/0000-0002-5522-4699>

Thu Pham
<https://orcid.org/0009-0002-7715-7113>

Ankona Banerjee
<https://orcid.org/0000-0003-4433-5446>

James Noel
<https://orcid.org/0000-0003-2381-7227>

Funding

None.

Conflict of Interest

The authors have no financial conflicts of
interest.

ABSTRACT

Purpose: Gastrostomy granulomas frequently occur in pediatric patients with gastrostomy tubes, yet there is a notable lack of comprehensive data on the efficacy and safety of various treatment modalities. Commonly used treatments, such as silver nitrate, are often painful and require frequent clinic visits, posing challenges for patients and families. Additionally, research on home-based treatments is limited, despite their potential to offer more convenient and less painful alternatives. This study addresses the need for well-designed comparisons of different treatment options.

Methods: We conducted a prospective, open-label study at the Children's Hospital of San Antonio, enrolling 36 pediatric patients aged 6 months to 17 years with gastrostomy tubes. Patients were randomized into two groups: one treated with topical silver nitrate and the other with table salt, excluding those on chemotherapy or with immunologic disorders. Granuloma sizes were measured at the study's start with blinded physicians analyzing photographs to assess size reduction, and parent satisfaction surveys were conducted to evaluate treatment acceptability and side effects.

Results: The median reduction in granuloma size was significantly greater in the table salt group (3.12 mm) compared to the silver nitrate group (2.25 mm) (Wilcoxon p -value=0.04). Parental satisfaction and confidence were high in both groups, with minor, self-limited skin irritation reported as a side effect.

Conclusion: The study suggests that table salt could be a feasible, non-inferior, and cost-effective alternative to silver nitrate for treating gastrostomy granulomas in pediatric patients. Further research with a larger sample size is necessary to validate these findings.

Keywords: Gastric feeding tubes; Enteral nutrition; Granulation tissue; Silver nitrate; Sodium chloride; Pediatric hospitals; Gastroenterology

INTRODUCTION

Granulation tissue is a common issue that arises after the insertion of gastrostomy tubes and buttons in children, with an occurrence rate of up to 69% [1]. Therapies used to treat granulation tissue include silver nitrate, topical steroids, stoma adhesive powder, topical antibiotics, and table salt. Each treatment is thought to be effective, however, no prospective studies have compared the effectiveness of these treatments. Silver nitrate cauterization

of granulation tissue is considered a common first-line approach for the treatment of granulation tissue [2-4]. However, it is discouraged when used by inexperienced clinicians because of the risk of causing damage to the tube and possible chemical burns to the site [3,5]. Additionally, the mode of action of silver nitrate causes trauma to the wound, promoting further inflammation and increasing the risk of infection developing [6]. Silver nitrate treatments can also be painful and often require clinic or inpatient application causing disruption to the lives of patients and families. Alternatively, treating granulation tissue with table salt allows families to treat granulation tissue at home with the potential for fewer adverse effects and a significantly lower cost burden to patients and families than traditional treatment modalities. Tanaka et al. [7] was a prospective case-series review of pediatric patients aged 5 months to 15 years which focused on the use of sprinkled table salt applied to granulation tissue overlying the gastrostomy tube site over a 2-year period. The study demonstrated a reduction of granulation tissue in 100% of patients, however, it was a very small study with only 8 patients and there was no comparative control group. In light of the aforementioned issues related to silver nitrate treatment and the promising results from the Tanaka et al. [7] study, it is crucial to further investigate the efficacy and potential benefits of using table salt in the management of granulation tissue in pediatric patients with gastrostomy tubes. This paper will present an original research study that prospectively compares the effectiveness, tolerability, and cost implications of table salt and silver nitrate in treating granulation tissue. By providing a comparative analysis, this study aims to contribute valuable insights to the existing body of knowledge, potentially informing clinical practice and patient care strategies.

MATERIALS AND METHODS

We conducted a prospective, open-label study, wherein we enrolled a total of 36 patients. The Institutional Review Board at the Children's Hospital of San Antonio granted approval for this study (No. H-46764) and written informed consent. Patients were selected to enroll in the study if they were between the ages of 6 months and 17 years of age and had gastrostomy tubes placed because they were unable to consume adequate nutrition orally or for medication administration. Patients receiving chemotherapy or diagnosed with immunologic disorders were excluded. The patients were randomized into two groups: topical silver nitrate and a second group using table salt treatment. The table salt group was pre-treated with 1mL of topical OTC lidocaine (Aspercreme 4% Lidocaine Pain Relieving Crème) and subsequently had 1/3 teaspoon of common table salt (Morton's Iodized Table Salt) applied to the granuloma on days 1, 2, 3, 4, 5, and 6 once a day. Parents were instructed on how to continue the salt treatment at home, emphasizing that the table salt needed to be applied for at least 15 minutes daily. The silver nitrate group had silver nitrate applied to the granuloma on days 1 and 4 with the option for pre-treatment with 1 mL of topical OTC lidocaine.

An L-shaped photomacrographic scale (ABFO No.2 #1005951) was used to measure the granuloma maximum radius at the study start and at the finish (days 1 and 7). As part of our data collection process, we used photographs of the granulomas and completed parent surveys for a qualitative understanding of the process. Both groups had precise measurements on day 1 and day 7 +/- 1 day (24 hours). The two study physicians blinded to the treatment analyzed the photographs and measured the maximum radius of the granuloma lesion at the study beginning and at the study end to calculate granuloma size difference. The physicians blinded to the treatment, then scored the pictures from the start

of the study, and at the study completion. Reduction in size was determined by subtracting measurement of maximum radius at the conclusion of the study from the maximum radius on study day 7. Patient satisfaction surveys attached to end of protocol with treatment were given to each patient's care-giving team at the conclusion of the study (day seven) and were entered into an online survey tool, survey monkey using an electronic device. Questionnaires focused on subjective satisfaction of the treatment, confidence in providing the therapy at home and side effects. Answers provided were on a three-point scale from very dissatisfied to neutral to very satisfied. Paper copies of the survey were used if an electronic device was not available. An electronic database was used for all survey uploads that did not contain any PHI.

RESULTS

Of the 36 participants, 12 were lost to follow-up, leaving 14 in the salt group and 10 in the silver nitrate group (**Fig. 1**). The mean and median ages of the participants were 5.12 and 3.2 years, respectively, with an age range of 8 months to 15 years. The average gastrostomy tube indwelling time was 31.3 months in the silver nitrate group and 35.5 months in the salt group (Fisher Exact test, $p=0.82$). The majority of patients had a low-profile Avanos MIC-KEY 14 French gastrostomy tube. Weight-for-length percentiles were balanced between both groups. There were no statistically significant differences between the groups in terms of weight, gastrostomy tube time, age, ethnicity, gender, or tube type. More detailed data are available in **Table 1**.

The average (\pm standard deviation, SD) granuloma size at pre-assessment was 8.83 (± 4.6) mm for the salt group and 5.3 (± 3.4) mm for the silver nitrate group. Post-assessment, these sizes decreased to 5.72 (± 2.1) mm and 3.6 (± 2.0) mm, respectively. The median granuloma size reduction was 3.12 mm (interquartile range [IQR]: 2.12–4.25) in the salt group and 2.25 mm (IQR: 0.25–2.5) in the silver nitrate group (Wilcoxon p -value=0.04). The Wilcoxon test demonstrated a statistically significant reduction in granulation tissue size in the salt treatment group [median (IQR): 4.5 (1.5–5) mm] compared to the silver nitrate group [median (IQR): 2 (0–2.75) mm], with a p -value of 0.04 (**Table 2**). Data analysis showed that the average reduction in size between pre- and post-assessment scores for both physician raters was greater in the salt treatment group [mean 3.77 (± 3.55) mm] than in the silver nitrate group [mean 1.52 (± 1.57) mm], indicating that the salt treatment regimen was non-inferior (**Fig. 2**).

Parental satisfaction and confidence with the treatment procedures were generally high in both groups, with no statistically significant differences ($p>0.05$), further demonstrating the non-inferiority of the salt treatment regimen compared to the standard of care (**Fig. 3**). Minor skin

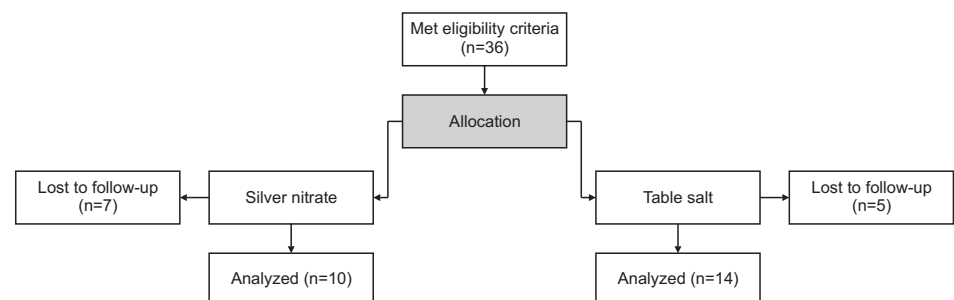


Fig. 1. Consort flow diagram.

Therapeutic Effect of Table Salt on Gastrostomy Granulomas

Table 1. Demographic and clinical characteristics

	Silver nitrate (SOC) (N=10)	Salt treatment (N=14)	Overall (N=24)	p-value
Sex				0.104
Male	8 (80.0)	6 (42.9)	14 (58.3)	Fisher's exact test
Female	2 (20.0)	8 (57.1)	10 (41.7)	
Ethnicity				1
Caucasian	3 (30.0)	4 (28.6)	7 (29.2)	Fisher's exact test
Hispanic	6 (60.0)	9 (64.3)	15 (62.5)	
Asian	0 (0.0)	0 (0)	0 (0.0)	
African American	1 (10.0)	1 (7.1)	2 (8.3)	
Weight-for-length (<2) or BMI (>2 years) Z score				0.748
1 to 2+	4 (40.0)	4 (28.6)	8 (33.3)	
0 to 1+	2 (20.0)	5 (35.7)	7 (29.2)	
-1 to 0	4 (40.0)	4 (28.6)	8 (33.3)	
-2 to -1	0 (0)	1 (7.1)	1 (4.2)	
Age (yr)				0.598
Mean (SD)	4.96 (3.29)	5.23 (4.86)	5.12 (4.20)	Kruskal-Wallis test
Median (range)	3.90 (2.00-10.9)	3.20 (0.800-15.8)	3.20 (0.800-15.8)	
Median (IQR)	3.90 (2.35-6.10)	3.20 (1.90-6.40)	3.20 (2.15-6.43)	
Gastrostomy tube type				0.805
Traditional Percutaneous Tube (Avanos)	0 (0.0)	0 (0.0)	0 (0.0)	Fisher's exact test
Low Profile Gastrostomy tube (Avanos)	8 (80.0)	10 (71.4)	18 (75.0)	
Low Profile Gastrostomy tube (AMT)	1 (10.0)	3 (21.4)	4 (16.7)	
Low Profile Gastrojejunostomy tube (AMT)	0 (0.0)	0 (0.0)	0 (0.0)	
Low Profile Gastrojejunostomy tube (Avanos)	1 (10.0)	1 (7.1)	2 (8.3)	
Duration of gastrostomy tube months				0.578
Mean (SD)	31.3 (23.4)	35.5 (40.7)	33.7 (34.0)	Kruskal-Wallis test
Median (range)	24.9 (1.00-77.5)	20.5 (1.00-152)	21.8 (1.00-152)	
Median (IQR)	24.9 (18.9-39.7)	20.5 (9.00-47.2)	21.8 (12.2-45.3)	
Does patient have history of treatment for granulation tissue?				0.172
No	1 (10.0)	6 (42.9)	7 (29.2)	Fisher's exact test
Yes	9 (90.0)	8 (57.1)	17 (70.8)	

Values are presented as number (%), mean (SD), median (range), or median (IQR).
BMI: body mass index, SD: standard deviation, IQR: interquartile range.

irritation was reported as a side effect in both groups. In the salt group, there were two reports of skin irritation that prompted clinic visits; however, the associated rash was self-limited in all cases (**Fig. 4**). Please refer to **Supplementary Fig. 1** for examples of treatment comparisons.

DISCUSSION

Our findings suggest that table salt may serve as a viable alternative to silver nitrate for the treatment of gastrostomy granulomas in pediatric patients. Interestingly, the salt treatment was associated with a slightly larger mean reduction in granuloma size compared to the silver nitrate group. High parental satisfaction and confidence with both treatment procedures were observed, further supporting the feasibility of these treatment regimens. This is particularly significant for the table salt treatment, as it represents a home-based, cost-effective alternative that could potentially reduce the burden on healthcare systems by minimizing the need for frequent hospital visits. Despite minor skin irritation reported as a side effect in both treatment groups, it was self-limiting in all cases, indicating that both treatments were generally well-tolerated. The balanced ethnicity distributions and non-significant age differences among the groups further support the generalizability of our findings.

Therapeutic Effect of Table Salt on Gastrostomy Granulomas

Table 2. Reviewer assessment of granulation tissue

	Silver nitrate (SOC) (N=10)	Paired Wilcoxon test	Salt treatment (N=14)	Paired Wilcoxon test	Overall (N=24)	p-value
Reviewer 1: Pre Reading						0.814
Mean (SD)	8.00 (1.89)	0.125	9.43 (5.85)	0.004	8.83 (4.61)	Kruskal-Wallis test
Median (range)	8.00 (5.00–11.0)	Paired Wilcoxon test	8.00 (3.00–25.0)	Paired Wilcoxon test	8.00 (3.00–25.0)	
Median (IQR)	8.00 (6.50–9.00)		8.00 (6.00–11.8)		8.00 (6.00–10.3)	
Reviewer 1: Post Reading						0.237
Mean (SD)	6.50 (2.64)		4.50 (3.67)		5.33 (3.37)	Kruskal-Wallis test
Median (range)	6.00 (3.00–11.0)		5.00 (0–10.0)		5.50 (0–11.0)	
Median (IQR)	6.00 (4.25–8.75)		5.00 (0.500–6.00)		5.50 (3.75–8.25)	
Reviewer 2: Pre Reading						0.654
Mean (SD)	5.45 (1.61)	0.036	5.93 (2.46)	0.002	5.73 (2.12)	Kruskal-Wallis test
Median (range)	5.00 (3.00–9.00)	Paired Wilcoxon test	5.50 (2.50–10.0)	Paired Wilcoxon test	5.00 (2.50–10.0)	
Median (IQR)	5.00 (5.00–5.75)		5.50 (4.25–7.75)		5.00 (4.88–7.00)	
Reviewer 2: Post Reading						0.699
Mean (SD)	3.90 (2.51)		3.32 (1.54)		3.56 (1.97)	Kruskal-Wallis test
Median (range)	3.50 (0–9.00)		3.75 (0–6.00)		3.75 (0–9.00)	
Median (IQR)	3.50 (2.25–5.00)		3.75 (3.00–4.00)		3.75 (2.75–4.25)	
Difference between pre and post for Reviewer 1						0.043
Mean (SD)	1.50 (2.32)		4.93 (6.20)		3.50 (5.18)	Kruskal-Wallis test
Median (range)	2.00 (–3.00–5.00)		4.50 (0–25.0)		3.00 (–3.00–25.0)	
Median (IQR)	2.00 (0–2.75)		4.50 (1.50–5.00)		3.00 (0–5.00)	
Difference between pre and post for Reviewer 2						0.156
Mean (SD)	1.55 (1.71)		2.61 (1.81)		2.17 (1.81)	Kruskal-Wallis test
Median (range)	1.25 (0–5.00)		2.50 (–1.00–5.00)		2.00 (–1.00–5.00)	
Median (IQR)	1.25 (0–2.75)		2.50 (2.00–4.00)		2.00 (0.750–3.25)	
Difference between pre and post between Reviewer 1 and 2						0.039
Mean (SD)	1.53 (1.57)		3.77 (3.55)		2.83 (3.06)	Kruskal-Wallis test
Median (range)	2.25 (–1.50–3.25)		3.13 (0–15.0)		2.50 (–1.50–15.0)	
Median (IQR)	2.25 (0.250–2.50)		3.13 (2.13–4.25)		2.50 (1.56–3.50)	

SD: standard deviation, IQR: interquartile range.

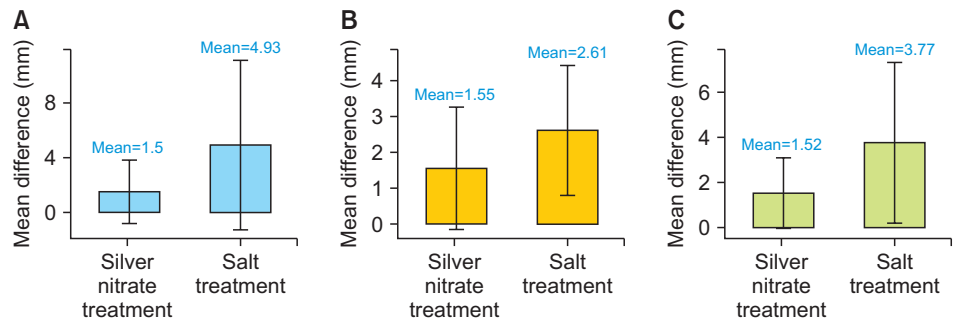


Fig. 2. (A) Mean difference in reduction of granulation tissue size (Reviewer 1). (B) Mean difference in reduction of granulation tissue size (Reviewer 2). (C) Mean difference in reduction of granulation tissue size (Averages).

Our findings, while promising, are preliminary and warrant further validation, particularly for the table salt treatment. Future studies involving a larger sample size are needed to confirm our findings and to further investigate the dose effect of table salt in treating gastrostomy granulomas. Of note, while not statistically significant, there were more males in the silver nitrate group, which could have influenced the results. Additionally, while most patients elected to use lidocaine as a pre-treatment, not all participants did in the silver nitrate group did, which could have affected the attrition rate (though the attrition rate was slightly higher in the salt group). To improve future research design, several considerations should be taken into account. First, increasing the number of participants will enhance the statistical power of the study and allow for more robust conclusions. Ensuring a more balanced distribution of males and females between groups will help mitigate any potential

Therapeutic Effect of Table Salt on Gastrostomy Granulomas

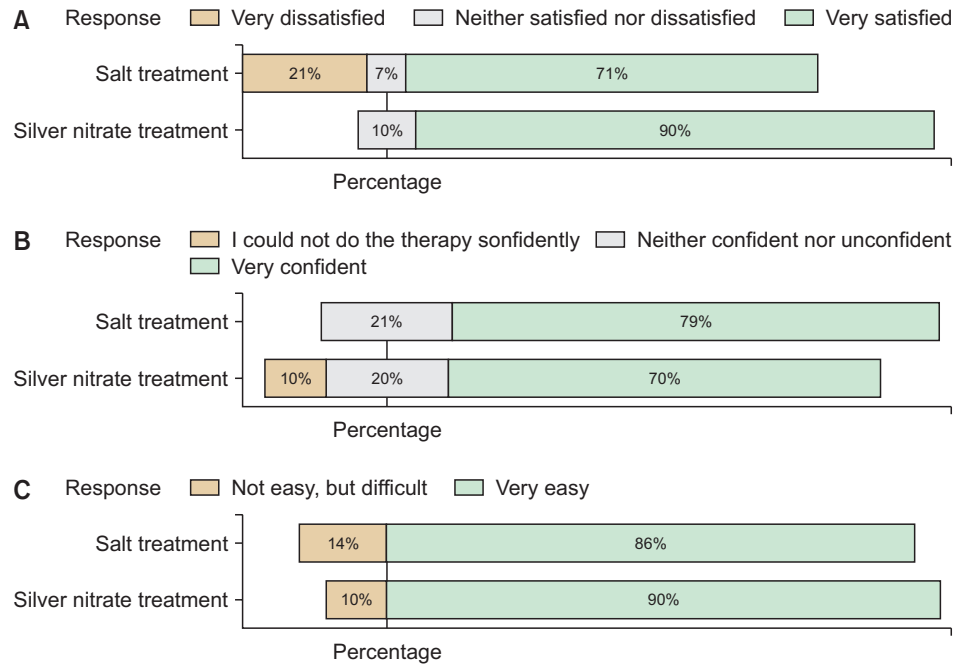


Fig. 3. (A) Parental rating of satisfaction with the duration to treatment efficacy. (B) Parental confidence to provide therapy for granulation tissue at home. (C) Parental report of difficulty level associated with therapy modality.

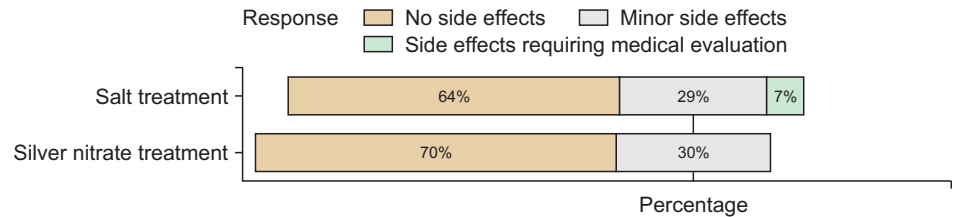


Fig. 4. Parental report of side effects associated with different treatment modalities.

gender-related biases. Standardizing the use of lidocaine or other pre-treatment anesthetics across all participants could help control for variability in pain tolerance and treatment response. Longer follow-up periods may provide more comprehensive data on the long-term efficacy and safety of the treatments. Additionally, future research could compare the effectiveness of table salt with other standard treatments such as topical triamcinolone and stoma adhesive powder to establish a more comprehensive understanding of its relative effectiveness.

In conclusion, our study points to the potential of table salt as a readily available, cost-effective, and non-inferior treatment for gastrostomy granulomas in pediatric patients. The observed reduction in granuloma size and high parental satisfaction highlight its feasibility as a home-based treatment option. However, more research is required to firmly establish its place in treatment protocols and to ensure its safety and efficacy across diverse patient populations. Future studies involving larger sample sizes and addressing the aforementioned design improvements are essential to confirm our findings and optimize treatment strategies. Additionally, it would be valuable to explore the long-term outcomes and potential benefits of integrating table salt treatment with other standard care practices. By addressing these areas, we can develop a more comprehensive understanding of the role of table salt in managing gastrostomy granulomas and potentially improve patient care.

ACKNOWLEDGEMENTS

Thank you to Lauren Del Bosque, Dr. Anthoula Christodoulou and Dr. Frances Hanson for their data collection. Thank you to Dr. McLoughlin for being a physician evaluator. Thank you to Dr. Adam Noel for his mentorship and guidance.

SUPPLEMENTARY MATERIAL

Supplementary Fig. 1

(A) Pre and post treatment salt group. (B) Pre and post treatment silver nitrate group.

REFERENCES

1. León AH, Hebal F, Stake C, Baldwin K, Barsness KA. Prevention of hypergranulation tissue after gastrostomy tube placement: A randomised controlled trial of hydrocolloid dressings. *Int Wound J* 2019;16:41-6. [PUBMED](#) | [CROSSREF](#)
2. Hirotsu K, Kannan S, Jiang SIB. Treatment of hypertrophic granulation tissue: a literature review. *Dermatol Surg* 2019;45:1507-16. [PUBMED](#) | [CROSSREF](#)
3. Goldberg E, Barton S, Xanthopoulos MS, Stettler N, Liacouras CA. A descriptive study of complications of gastrostomy tubes in children. *J Pediatr Nurs* 2010;25:72-80. [PUBMED](#) | [CROSSREF](#)
4. Crawley-Coha T. A practical guide for the management of pediatric gastrostomy tubes based on 14 years of experience. *J Wound Ostomy Continence Nurs* 2004;31:193-200. [PUBMED](#) | [CROSSREF](#)
5. Nelson L. Wound care. Points of friction. *Nurs Times* 1999;95:72, 75. [PUBMED](#)
6. Verga E, Chohan B, Verdolini R. Stoma complications: corticosteroid and silver nitrate-resistant inflammation successfully treated with topical tacrolimus. *Dig Surg* 2017;34:518-20. [PUBMED](#) | [CROSSREF](#)
7. Tanaka H, Arai K, Fujino A, Takeda N, Watanabe T, Fuchimoto Y, et al. Treatment for hypergranulation at gastrostomy sites with sprinkling salt in paediatric patients. *J Wound Care* 2013;22:17-8, 20. [PUBMED](#) | [CROSSREF](#)